

Research Paper: Prevalence of Neurovascular Pathologies: A Study on the First 18 Month Activity of Firoozgar Hospital



Mohammad Ghorbani¹, Sima Sheikh Ghomi^{2*}

1. Department of Neurosurgery, Firoozgar General Hospital, Iran University of Medical Sciences, Tehran, Iran
2. Department of Medical Education, School of Medicine, Iran University of Medical Sciences, Tehran, Iran



Citation Ghorbani M, Sheikh Ghomi S. Prevalence of Neurovascular Pathologies: A Study on the First 18 Month Activity of Firoozgar Hospital. Iran J Neurosurg. 2018; 4(1):35-40. <http://dx.doi.org/10.32598/irjns.4.1.35>

doi: <http://dx.doi.org/10.32598/irjns.4.1.35>

Funding: See Page 38

Copyright: The Author(s)

Article info:

Received: 15 August 2017

Accepted: 25 November 2017

Available Online: 01 January 2018

Keywords:

Neurosurgery, Angiography, Brain

ABSTRACT

Background and Aim: Endovascular neurosurgery is widely accepted as a useful modality for the management of neurovascular disorders. This retrospective study aimed to evaluate the causes of diagnostic and therapeutic neuroendovascular procedures, as well as the prevalence, type, location and management of vascular pathologies observed in Firoozgar Hospital, Tehran City, Iran.

Methods and Materials/Patients: In this study, we analyzed the causes and outcomes of the neuroendovascular procedures during 18 months from February 2013 to September 2014 in Firoozgar Hospital, Tehran, Iran.

Results: In total, 724 diagnostics and therapeutic neuroendovascular procedures were performed on 561 patients. The mean (SD) age of the patients was 44.83(18.73) years and 598(50.27%) of them were females. The most prevalent cause of these procedures was cryptogenic intracranial hemorrhages (24.58%), followed by ruling out vascular lesions due to suspicious MRI without neurological defects (14.91%), and suspicious MRI with focal neurologic defects (11.74%).

Conclusion: Endovascular neurosurgery plays a key role in diagnosis and treatment of the most prevalent neurovascular disorders in our referral center.

1. Introduction

Angiography is a creative way to reveal alive human vascular anatomy and enables simultaneous endovascular treatment. Benefits of this technique are very prominent in performing surgery on the highly complex vascular system of brain.

Cerebral or spinal vascular lesions including aneurysms, Arteriovenous Malformations (AVMs), dural arteriovenous fistula, carotid cavernous fistula, intracranial atherosclerosis, carotid or vertebral dissection, can be a dangerous threat to sufficient blood supply of central nervous system. Neuroendovascular procedures and their advances have targeted these lesions for decades [1-3].

* Corresponding Author:

Sima Sheikh Ghomi, MD

Address: Department of Medical Education, School of Medicine, Iran University of Medical Sciences, Tehran, Iran

Tel: +98 (912) 8265585

E-mail: sshaikhghomi@yahoo.com



Currently, many neurovascular centers are involved in endovascular management of cerebrovascular diseases worldwide and different techniques and devices are introduced to the interventional neuroradiology and, the appliance of which depend on the patient's conditions and symptoms, the vascular lesion and its anatomic site, as well as the interventionist's experience and preference [4, 5, 8-13].

Firoozgar Hospital is an educational and tertiary Medical Care Center located in Tehran, Iran. Many patients are referred to this hospital from all over the country. Interventional Neuroendovascular Department of this hospital opened in February 2013. The main aim of this study was to report Firoozgar hospital activities during the first 18 months after opening this department.

2. Methods & Materials/Patients

In this descriptive and cross-sectional study, we analyzed the indications and findings of all 724 diagnostics and therapeutic neurovascular angiographies performed on 561 patients during the 18 months period from February 2013 to September 2014. We collected and analyzed the information about the age, gender, angiographies indications, as well as the type of vascular lesions and their locations found in catheter angiograms. However, we lacked information about the outcomes and rate of mortality of procedures.

3. Results

In total, 724 diagnostics and therapeutic neuroendovascular angiographies were performed on 561 patients during the first 18 months activity of this center. The mean (SD) age of the 561 patients was 44.83(18.73) years and 282(50.3%) patients were female. The most prevalent indication of these procedures was cryptogenic intracranial hemorrhages (24.58%), followed by ruling out vascular lesions due to suspicious MRI without neurological defects (14.91%), and suspicious MRI with focal neurologic defects (11.74%) (Figure 1).

Twenty-six patients received trigeminal neuralgia treatment by Mullans technique and 14 were also referred for superselective intra-arterial chemotherapy treatment of ocular retinoblastoma. The neurovascular angiographies done on the remaining 521 patients were because of their diagnosis and endovascular treatment of neurovascular lesions. Of them, 181 patients had normal catheter angiograms.

In other words, vascular lesions were seen in 340 patients which cerebral aneurysms (40.00%), AVMs (21.47%) and cerebral vascular stenosis or occlusion (10.59%) were the most common cases. Table 1 presents the frequency of vascular lesion in details.

As noted, brain aneurysms were the most common vascular lesion in the patients. In addition, 0.9% had multiple aneurysms and the most prevalent location of single aneurysm was anterior communicating artery (27.64%). Finally, 33.09% of patients with cerebral aneurysm received open surgical treatment (clipping), and 34.56% of them underwent endovascular surgery (coiling). No intervention was done on 30.15% of them due to lack of indication, patient dissatisfaction, or other hospital referral. Additionally, 3(2.21%) patients were treated by combined open and endovascular surgery. After aneurysms, cerebral AVM was in the second place of neurovascular lesions, that affected 73 patients. Also, 85.93% of brain AVMs were located in supratentorial territory (73.43% in superficial and 12.50% in deep regions), and 14.06% of AVMs were at the infratentorial level.

Lastly, 58.70% of AVMs were managed by endovascular embolization (complete occlusion in 28 patients and partial occlusion in 15 patients), 8.10% by open surgical procedures, 2.73% by radiosurgery and 8.10% by combination of radiosurgery and endovascular surgery. The remaining 22.37% of patients were not treated due to lack of indication, patient dissatisfaction with treatment, or inappropriate access to the AVM location.

The third neurovascular lesion of the studied patients was atherosclerotic cerebral arteries stenosis or occlusion. About 88.89% of these lesions were seen in extra- or intra-cranial arteries and 11.11% in vertebral arteries. In the following step, endovascular stent or balloon angioplasty was performed on 44.44% of them, according to severity of the stenosis as well as the patient's symptoms and general conditions. The rest were managed by surveillance and medical therapy.

Head and neck tumors (excluding pediatric retinoblastomas) were seen in 8.53% of the patients. High vascular tumors constituted 86.75% of them and were mostly located in skull base and posterior fossa. Endovascular embolization was applied for 100% of high vascular tumors.

Spinal vascular lesions seen in 23 patients included Spinal dAVFs (16 patients), AVMs (4 patients), and vascular tumors (3 patients). Endovascular procedures and

Table 1. Frequency of neurovascular lesions

Vascular Lesion	Number of Patients	Percentage
Cerebral aneurysm	136	40.00
Cerebral AVM	73	21.47
Cerebral arteries stenosis/occlusion	36	10.59
Head and neck tumors/masses	29	8.53
Spinal vascular lesions	23	6.76
Carotid Cavernous fistulae	12	3.53
Carotid/vertebral dissection	11	3.24
Dural arteriovenous fistula	10	2.94
Venous sinus thrombosis	4	1.18
Cerebral proliferative angiopathy	3	0.88
Cerebral dolicoectasia	2	0.59
Moyamoya disease	1	0.29
Total	340	100.0



open surgeries were applied for 39.13% and 21.47% of them, respectively. Carotid Cavernous Fistulae (CCFs) also constituted 3.53% of neurovascular lesions which all were managed by endovascular surgery.

Carotid/Vertebral dissections formed 3.24% of the lesions, of which 65.82% mainly received medical therapy and the rest (34.18%) were treated by arterial embolization. Dural arteriovenous fistulas were other vascular lesions that 40.00% of them were embolized.

Venous sinus thrombosis, cerebral proliferative angiopathy, cerebral vascular dolicoectasia and Moyamoya disease were less common lesions and were exclusively managed by surveillance.

4. Discussion

Because of the presence of pediatric patients with ocular retinoblastoma, the mean age of the study participants was 5-10 years lower than the average age of the

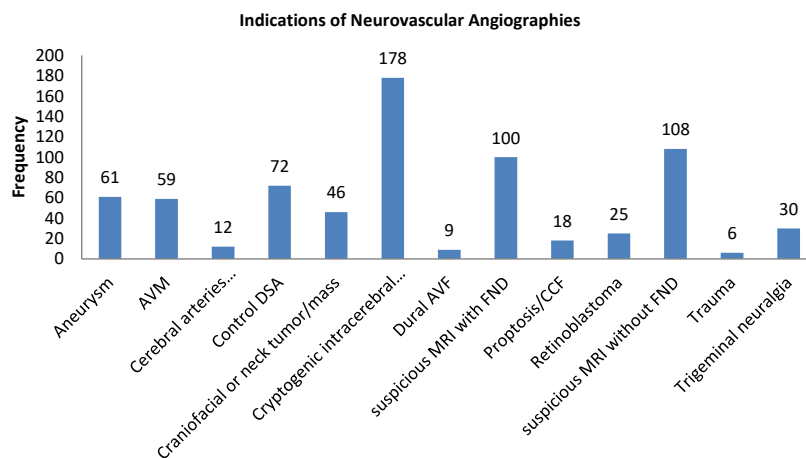


Figure 1. Distribution of indications of neurovascular catheter angiographies



patients in similar studies [14-21]. In this study, women constituted nearly half of the patients which is incompatible with gender distribution of the related previous studies [14-17].

As stated in the results section, cryptogenic intracranial hemorrhage was the most common indication for neurovascular angiography, during the first 18 months activity of this center. This result is in line with the study by Saviris et al. in the USA, in which subarachnoid hemorrhages and stroke symptoms were identified as the most prevalent causes. Furthermore, unruptured cerebral aneurysms and subarachnoid hemorrhages were the main causes of cerebral angiographies in the study conducted by FiFi and associates [14-16].

In our study, cerebral aneurysms (40.00%) and cerebral AVMs (21.47%), were the main abnormal neurovascular findings. In a relatively similar descriptive study conducted by Gharib Salehi et al. in Kermanshah, on 143 cases with non-traumatic intracranial hemorrhage, aneurysms and AVMs constituted the most common causes [17].

As noted earlier, anterior communicating arteries was the main site of cerebral aneurysms and cerebral AVMs were more located in supratentorial level. Additionally, our study showed that carotid arteries were the most involved artery in atherosclerotic stenosis. All of our findings about the location of common neurovascular lesions are consistent with the results of relevant previous articles [14, 18-22].

5. Conclusion

Endovascular neurosurgery plays a key role in diagnosis and treatment of most neurovascular disorders in our referral center.

Ethical Considerations

Compliance with ethical guidelines

There was no ethical principles to be considered in this research.

Funding

This research did not receive any specific grant from funding agencies in the public, commercial, or not-for-profit sectors. This article was adapted from MD dissertation of Sima Sheikghomi in the Department of

Medical Education, School of Medicine, Iran University of Medical Sciences, Tehran, Iran.

Conflict of interest

The authors declared no conflict of interest.

References

- [1] Liu HM. Current status of interventional neuroradiology (Neurointerventional surgery). *Journal of Buddhist Compassion Relief Tzu Chi Foundation*. 2008; 20(3):177-87. [DOI:10.1016/S1016-3190(08)60033-6]
- [2] Berg R. Neurovascular diseases: From angiography to management. *European Journal of Radiology*. 2003; 46(3):169-71. [DOI:10.1016/S0720-048X(03)00088-3]
- [3] Khatri R, Gomez CR, Qureshi AI. Interventional neuroimaging. *Neurologic Clinics*. 2008; 27(1):109-37. [DOI:10.1016/j.ncl.2008.09.002] [PMID]
- [4] Liebman KM, Severson MA. Techniques and devices in neuroendovascular procedures. *Neurosurgery Clinics of North America*. 2009; 20(3):315-40. [DOI:10.1016/j.nec.2009.01.002] [PMID]
- [5] Lanzino G, Rabinstein AA. Endovascular neurosurgery in the United States: A survey of 59 vascular neurosurgeons with endovascular training. *World Neurosurgery*. 2011; 75(5-6):580-85. [DOI:10.1016/j.wneu.2011.02.021] [PMID]
- [6] Peschillo S, Delfini R. Endovascular neurosurgery in Europe and in Italy: What is in the future?. *World Neurosurgery*. 2012; 77(2):248-51. [DOI:10.1016/j.wneu.2011.05.055] [PMID]
- [7] Deshmukh VR, Fiorella DJ, McDougall CG, Spetzler RF, Albuquerque FC. Preoperative embolization of central nervous system tumors. *Neurosurgery Clinics of North America*. 2005; 16(2):411-32. [DOI:10.1016/j.nec.2004.08.010] [PMID]
- [8] Kirmani JF, Janjua N, Kawi AA, Ahmed Sh, Khatri I, Ebrahimi A, et al. Therapeutic advances in interventional neurology. *NeuroRX*. 2005; 2(2):304-23. [DOI:10.1602/neurorx.2.2.304] [PMID] [PMCID]
- [9] Sekhar LN, Biswas A, Hallam D, Kim LJ, Douglas J, Ghodke B. Neuroendovascular management of tumors and vascular malformations of the head and neck. *Neurosurgery Clinics*. 2009; 20(4):453-85. [DOI:10.1016/j.nec.2009.07.007] [PMID]
- [10] Boschi A, Barbagli G, Ashraf-Noubari B, Cipolleschi E, Mangiafico S, Ammannati F. A rare association between meningioma and two intracranial vascular lesions: Case report and review of literature. *Iranian Journal of Neurosurgery*. 2016; 2(1):22-4. [DOI:10.18869/acadpub.irjns.2.1.22]
- [11] Valavanis A, Christoforidis G. Applications of interventional neuroradiology in the head and neck. *Seminars in Roentgenology*. 2000; 35(1):72-83. [DOI:10.1016/S0037-198X(00)80034-6]
- [12] Duffis EJ, Tank V, Gandhi CD, Prestigiacomo CJ. Recent advances in neuroendovascular therapy. *Clinical Neurology and Neurosurgery*. 2013; 115(7):853-8. [DOI:10.1016/j.clineuro.2013.01.015] [PMID]

- [13] Johnson MH, Chiang VL, Ross DA. Interventional neuroradiology adjuncts and alternatives in patients with head and neck vascular lesions. *Neurosurgery Clinics of North America*. 2005; 16(3):547-60. [DOI:10.1016/j.nec.2005.04.007] [PMID]
- [14] Harsha KJ. Successful endovascular neurosurgical practice in resource-poor exclusive rural neuro-hospital setup. *Journal of Neurosciences in Rural Practice*. 2016; 7(5):13–7. [DOI:10.4103/0976-3147.196459] [PMID] [PMCID]
- [15] Sakai N, Yoshimura Sh, Taki W, Hyodo A, Miyachi Sh, Nagai Y, et al. [Recent trends in neuroendovascular therapy in Japan: analysis of a nationwide survey—Japanese Registry of Neuroendovascular Therapy (JR-NET) 1 and 2 (Japanese)]. *Neurologia Medico-Chirurgica*. 2014; 54(1):1–8. [DOI:10.2176/nmc.aa.2013-0197] [PMCID]
- [16] Fifi JT, Meyers PM, Lavine SD, Cox V, Silverberg L, Mangla S, et al. Complications of modern diagnostic cerebral angiography in an academic medical center. *Journal of Vascular and Interventional Radiology*. 2009; 20(4):442-47. [DOI:10.1016/j.jvir.2009.01.012] [PMID]
- [17] Gharib-Salehi M, Alimohammadi E, Bagheri SR, Saeidi-Brojeni H, Alireza Abdi, Akbary M, et al. Cerebral angiographic findings in Non-Traumatic Intracranial Hemorrhage: A single center experience in the west of Iran. *Iranian Journal of Neurosurgery*. 2017; 3(3):95-102 [DOI:10.29252/irjns.3.3.95]
- [18] Miri SM, Heidarzadeh C, Fakhr Tabatabai SA, Ghanaati H. Angiographic findings in patients with cerebral aneurysm. *Tehran University Medical Journal*. 2004; 62(4):310-14.
- [19] Tong X, Wu J, Lin F, Cao y, Zhao Y, Ning B, et al. The effect of age, sex, and lesion location on initial presentation in patients with brain arteriovenous malformations. *World Neurosurg*. 2016; 87:598-606. [DOI:10.1016/j.wneu.2015.10.060] [PMID]
- [20] Dmytriw AA, Ter Brugge KG, Krings T, Agid R. Endovascular treatment of head and neck arteriovenous malformations. *Neuroradiology*. 2014; 56(3): 227-36. [DOI:10.1007/s00234-014-1328-0] [PMID]
- [21] Luo J, Lv X, Jiang C, Wu Z. Brain AVM characteristics and age. *European Journal of Radiology*. 2012; 81(4):780-83. [DOI:10.1016/j.ejrad.2011.01.086] [PMID]
- [22] Borhani-Haghighi A, Emami M, Sadeghi Vasaksi A, Shariat A, Banhashemi MA, Alireza N, et al. Large-vessel stenosis in the patients with ischemic stroke in Iran: Prevalence, pattern, and risk factors. *Journal of Vascular and Interventional Neurology*. 2015; 8(1):11–6. [PMID] [PMCID]

