

Research Paper:

Predicting Unilateral Post-laminectomy C5 Palsy by Measuring C5 Exit Foramen Area on Preoperative Computed Tomography



Masoud Khadivi¹, Mohammad Reza Golbakhsh², Mersad Moosavi², Seyed Sina Ahmadi Abhari^{1*}

1. Department of Neurosurgery, Shariati Hospital, Tehran University of Medical Sciences, Tehran, Iran
2. Department of Orthopedic Surgery, Sina Hospital, Tehran University of Medical Sciences, Tehran, Iran



Citation: Khadivi M, Golbakhsh MR, Moosavi M, Ahmadi Abhari S. Predicting Unilateral Post-laminectomy C5 Palsy by Measuring C5 Exit Foramen Area on Preoperative Computed Tomography. Iran J Neurosurg. 2019; 5(3):103-108. <http://dx.doi.org/10.32598/irjns.5.3.2>

<http://dx.doi.org/10.32598/irjns.5.3.2>



Article info:

Received: 10 Dec 2018
Accepted: 03 Apr 2019
Available Online: 01 Jul 2019

Keywords:

Cervical Nerve Palsies, Laminectomy, Spinal Cord Disease, Spinal Osteophytosis, Cervical Vertebrae

ABSTRACT

Background and Aim: Postoperative C5 motor palsy is known as a common complication, not only after cervical laminectomy but also after anterior discectomy. There is no consensus on any of the proposed mechanisms of C5 palsy following posterior cervical decompression. It was found that C5 palsy is more common in patients with smaller C5 root foramen area. The purpose of this study was to define a cut-off value for C4-C5 foraminal area on preoperative computed tomography images to predict post-laminectomy C5 palsy.

Methods and Materials/Patients: In this prospective clinical study, C4-C5 foraminal area of 119 patients with cervical spondylotic myelopathy calculated on reformatted pure sagittal computed tomography images value was defined by measuring maximal height and transverse diameter of foramina and a cut-off in which with lesser amounts, post-laminectomy C5 palsy was more common.

Results: Of 119 patients with spondylotic myelopathy undergoing cervical laminectomy, 23 ones experienced postoperative C5 palsy with mean C4-C5 foraminal area of 44.54 ± 0.72 mm². Mean C5 root exit foraminal area in patients with intact post-operative root function was calculated 56.78 ± 5.48 mm² and the difference between these two groups was statistically significant ($P < 0.05$). No patient with C5 exit foraminal area more than 46 mm² had C5 palsy after laminectomy.

Conclusion: The incidence of post-laminectomy C5 palsy is significantly higher in patients with C5 exit foraminal area less than 46 mm². Prophylactic C4-C5 foraminotomy in this group may significantly reduce the risk of postoperative C5 nerve motor palsy, although the effect of this procedure is still debatable.

*** Corresponding Author:**

Seyed Sina Ahmadi Abhari, MD.

Address: Department of Neurosurgery, Shariati Hospital, Tehran University of Medical Sciences, Tehran, Iran

Tel: +98 (912) 3883369

E-mail: drsinaabhari@gmail.com



Highlights

- Postoperative C5 motor palsy is known as a common complication after cervical laminectomy.
- Patients with cervical spondylotic myelopathy and C4-C5 foraminal area smaller than 46 mm² measured on the preoperative computed tomographic scan are more prone to post-laminectomy unilateral C5 motor palsy.
- The role of prophylactic C5 foraminotomy in this group of patients is still controversial.

Plain Language Summary

Cervical canal stenosis is a common disorder affecting the elderly people. A group of these patients are proper candidates for surgical decompression of spinal cord applying posterior approaches, namely laminectomy, during which the lamina of the vertebrae is resected. This surgical procedure is accompanied by some complications, one of them is the inability of the patient to abduct shoulder after the operation. This happens because of damage to the ipsilateral fifth cervical nerve root. The exact mechanism has not been clearly understood yet, but stenosis of the aforementioned root exit zone from the spinal cord where it enters intervertebral foramen may be one of the mechanisms. The authors of this study measured the fifth cervical nerve root exit zone area of 119 patients that were candidate for cervical laminectomy by using a high-resolution computed tomographic scan. A total of 23 patients experienced an inability to abduct one shoulder after the operation. The mean exit zone area of the fifth cervical nerve root was significantly lower in these patients than the other group with intact shoulder function after laminectomy. The authors defined a cut-off value where almost all patients with the fifth cervical nerve root exit zone area lower than 46 mm² experienced impaired shoulder abduction after the operation. Controversy exist regarding the prophylactic widening of the above root exit zone as an option to reduce the risk of this complication since many authors believe that this procedure itself may increase the risk of fifth cervical nerve palsy.

1. Introduction

Laminectomy is a surgical option widely used in the treatment of cervical spondylotic myelopathy. Among all of the well-known complications of this procedure, motor dominant unilateral C5 root palsy is seen in 5-30% of patients that may occur without intraoperative nerve injury [1, 2]. This complication is determined as a weakness of deltoid or biceps brachii which may develop up to a week after posterior cervical decompression procedures [3]. Retraction of C5 nerve root caused by dorsal shifting of the cord after decompression i.e. tethering phenomenon [4], cord ischemia, reperfusion injury of the spinal cord [5] and thermal injury during bone drill have been proposed so far [6, 7], although none of these hypotheses alone can effectively account for all of the clinical characteristics of motor dominant C5 palsy [8].

Some investigators have shown narrowing of C5 root exit foramen in patients with post-laminoplasty C5 palsy but others have reported no difference between dimensions of C4-C5 and other cervical foramina in this group of patients. Although no criteria have been defined,

prophylactic C4-C5 foraminotomy is proposed as one of the strategies that may reduce the risk of this complication [9]. This procedure is not accepted by other surgeons [10].

In this study, the authors investigated whether the surface areas of C4-5 foramina in patients with spondylotic myelopathy who had experienced post-laminectomy C5 palsy were smaller than patients with normal C5 motor function after decompression or not. Also, we defined a cut-off value for C5 root exit foramen surface area in which with lesser amounts, C5 palsy has been seen in almost all patients.

2. Methods and Materials/Patients

This prospective study was performed after obtaining written informed consent from patients, explaining all the possible consequences of radiation exposure by computed tomography scan. Out of 132 recruited patients, 13 ones did not sign the informed consent and dropped out of the study. A series of 119 patients (96 females and 23 males) with an average age of 74.4 years (range of 64-88 years) that were candidates for cervical laminectomy without fusion were selected. Symp-

toms or signs of cervical spondylotic myelopathy on neurologic examination and/or cervical spinal cord T2 signal intensity change on Magnetic Resonance Imaging (MRI), also intact deltoid and biceps brachii muscles force were the inclusion criteria of this study. Prior history of any cervical spine operation, vertebral instability on dynamic flexion-extension radiologic images, C5 root motor dysfunction on preoperative physical examination and deterioration of symptoms of myelopathy were defined as the exclusion criteria.

Computed Tomography (CT) scan was performed before cervical laminectomy to calculate C4-C5 foraminal heights and transverse diameters on both sides. Scanning parallel to C4-C5 disc space was done using a 64-slice helical CT scanner with 1.5 mm thickness. The uttermost craniocaudal and anteroposterior diameters of C5 root exit foramina measured just lateral to laminofacet junction on high-resolution reformatted sagittal images (Figure 1). The foraminal area calculated using the ellipse area $\pi \times xy/2$ ($\pi=3.14$), where x and y are the maximal height and transverse diameter of foramen, respectively.

All 119 patients underwent surgery in a prone position with Mayfield® head holder on a Jackson table. The neck placed in slightly flexed position and shoulders gently taped to the foot of the bed. Standard laminectomy from C3 to C6 without fusion was done using high-speed drills and continuous irrigation with chilled water (10°C). No additional foraminotomy was performed. Patients who had had C5 root motor function impairment defined as weakness of the deltoid or

the biceps brachii muscles without deterioration of any symptom of myelopathy in neurologic examination one week after cervical laminectomy were identified. Mean C5 foraminal area in this group was compared with that of the patients who had intact C5 root motor function after decompression, using independent samples t-test on SPSS® software V. 16. Also, ROC curve analysis was performed to define a cut-off value for C4-C5 foraminal area in patients with post-laminectomy C5 palsy.

3. Results

Out of 119 consecutive patients who had undergone standard cervical laminectomy from C3 to C6 without fusion, 23 (10 males and 13 females) experienced unilateral C5 root motor impairment with mean age of 74.52 years. No statistically significant difference was found between age or gender of this group and patients with postoperative intact C5 root function. Mean C5 foraminal area was $44.54 \pm 0.72 \text{ mm}^2$ and $56.78 \pm 5.48 \text{ mm}^2$ in patients with C5 palsy and intact post-laminectomy root function, respectively. By using independent samples t-test, the difference was statistically significant ($P < 0.05$).

By using ROC curve analysis, the C4-C5 exit foramen area of 46 mm^2 was defined as the cut-off value for patients with post-laminectomy C5 palsy. The area under the curve was 99.3%. Sensitivity, specificity, Negative Predictive Value (NPV) and Positive Predictive Value (PPV) of this cut-off point to predict C5 palsy after decompression was 100, 97.7, 100 and 82.1%, respectively. Patients with C4-C5 foraminal area more than 46 mm^2

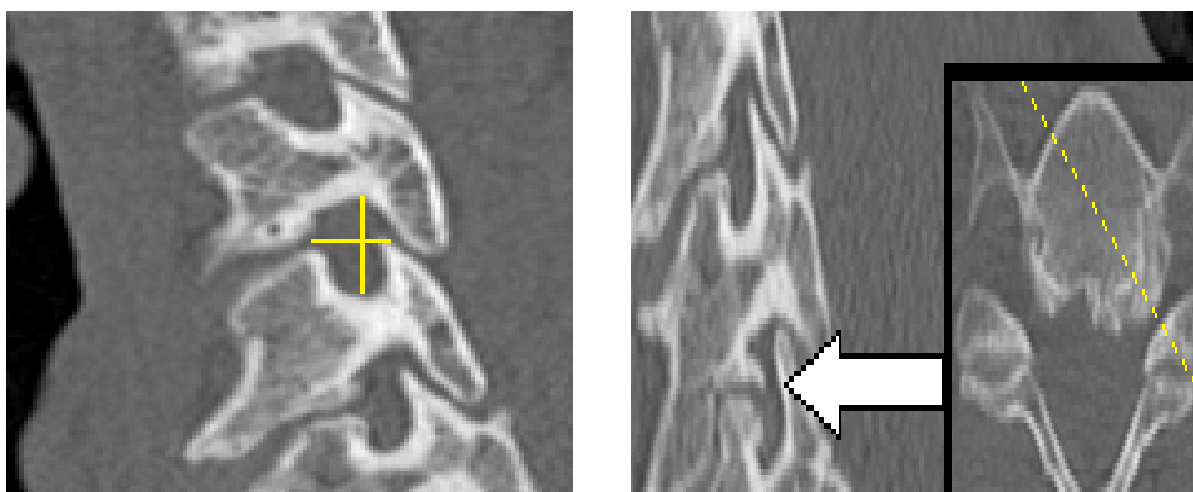


Figure 1. Measuring maximal height and transverse diameter of right C4-C5 foramen on Computed Tomography (CT) image



Left: The surface area of the right and left C5 root exit foramen in this patient is 58.40 mm^2 and 55.71 mm^2 , respectively. No new neurologic deficit was observed one week after cervical laminectomy without fusion. Right: The surface area of the right and left C5 root exit foramen in this patient is 48.20 mm^2 and 42.77 mm^2 , respectively. She experienced left C5 motor palsy after cervical laminectomy.

never experienced C5 palsy following cervical laminectomy. Out of 23 patients with post-laminectomy C5 palsy, 19 (82%) experienced complete resolution of mild paresis after a 3-month follow-up. Three patients with severe symptoms had partial recovery with physical therapy and one was lost at follow-up.

4. Discussion

As pointed out earlier, there is still a debate on the definite etiology of C5 palsy after posterior cervical decompression procedures [5]. This complication does not necessarily emerge in patients whose dorsal migration of the spinal cord is excessive after laminoplasty [11]. Moreover, C5 palsy after anterior cervical surgery cannot necessarily be accounted for this tethering hypothesis [12]. The exclusive pattern of palsy restricted to a single segment is difficult to explain by reperfusion of the spinal cord [2]. We eliminated thermal damage to the root due to high-speed drilling by continuous irrigation using chilled water. In this study, we found that there was a statistically significant difference between C5 exit foraminal area of patients with post-laminectomy C5 palsy and a group of patients with intact motor function of the mentioned nerve root.

We discovered that patients with cervical spondylotic myelopathy and C4-C5 foraminal area smaller than 46 mm² were more prone to post-laminectomy unilateral C5 motor palsy. There is no consensus on whether prophylactic C4-C5 foraminotomy would reduce the risk of this complication [10]. In fact, some researchers believe that this procedure itself may be one of the main reasons for C5 motor palsy [9]. Imagama et al. have shown statistically significant smaller C5 root foramen and larger superior articular process in patients with post-laminoplasty C5 radiculopathy [13]. A significant difference in the diameter of the C4-C5 foramen between patients with or without C5 palsy after cervical open-door laminoplasty has been reported by Katsumi et al. [9]. They suggested that the main etiology of C5 palsy could be preexisting C4-C5 foraminal stenosis [14]. Komagata and Sasai have reported that performing selective foraminotomy in addition to posterior central canal decompression would prevent C5 radiculopathy [10, 15].

5. Conclusion

In this study, we did not consider the effect of cervical sagittal profile on the incidence of post-laminectomy C5 root motor palsy, as many patients with spondylotic myelopathy have some degrees of positive cervical sagittal imbalance. Also, the effect of prophylactic foraminotomy was not evaluated.

Ethical Considerations

Compliance with ethical guidelines

This study was performed after all 119 patients signed the written informed consent, permitting the authors to fulfill this research with complete permission. All procedures were in accordance with the ethical standards of the institutional and/or national research committee and with the 1964 Helsinki declaration and its later amendments or comparable ethical standards.

Funding

There was no funding support, and all costs including CT scans were paid personally by the main investigator.

Authors contributions

Conceptualization and methodology, data collection and data analysis: Seyed Sina Ahmadi Abhari, Masoud Khadivi, and Mohammad Reza Golbakhsh; Drafting the article: Seyed Sina Ahmadi Abhari, Mersad Moosavi; Critically revising the article, reviewing the submitted version of manuscript, and Approving the final version of the manuscript: All authors.

Conflict of interest

The authors declared no conflict of interest.

Acknowledgments

The authors would like to thank the Research and Development Center of Shariati Hospital, Tehran for their assistance in performing the statistical procedures of this research.

References

- [1] Bydon M, Macki M, Kaloostian P, Sciubba DM, Wolinsky JP, Gokaslan ZL, et al. Incidence and prognostic factors of c5 palsy: A clinical study of 1001 cases and review of the literature. *Neurosurgery*. 2014; 74(6):595-605. [DOI:10.1227/NEU.0000000000000322] [PMID]
- [2] Nassr A, Eck JC, Ponnappan RK, Zanoun RR, Donaldson WF 3rd, Kang JD. The incidence of C5 palsy after multilevel cervical decompression procedures: A review of 750 consecutive cases. *Spine*. 2012; 37(3):174-8. [DOI:10.1097/BRS.0b013e318219cfe9] [PMID]
- [3] Hasegawa K, Homma T, Chiba Y. Upper extremity palsy following cervical decompression surgery results from a transient

- spinal cord lesion. *Spine*. 2007; 32(6):E197-202. [DOI:10.1097/01.brs.0000257576.84646.49] [PMID]
- [4] Tsuzuki N, Abe R, Saiki K, Zhongshi L. Extradural tethering effect as one mechanism of radiculopathy complicating posterior decompression of the cervical spinal cord. *Spine*. 1996; 21(2):203-10. [DOI:10.1097/00007632-199601150-00008] [PMID]
- [5] Kurosa Y. Pathophysiology of postoperative C5 nerve root palsy. *Spine & Spinal Cord*. 1993; 6:107-14.
- [6] Hosono N, Miwa T, Mukai Y, Takenaka S, Makino T, Fuji T. Potential risk of thermal damage to cervical nerve roots by a high-speed drill. *The Journal of Bone and Joint Surgery. British Volume*. 2009; 91(11):1541-4. [DOI:10.1302/0301-620X.91B11.22196] [PMID]
- [7] Takenaka S, Hosono N, Mukai Y, Tateishi K, Fuji T. Significant reduction in the incidence of C5 palsy after cervical laminoplasty using chilled irrigation water. *The Bone & Joint Journal*. 2016; 98(1):117-24. [DOI:10.1302/0301-620X.98B1.36042] [PMID]
- [8] Sakaura H, Hosono N, Mukai Y, Ishii T, Yoshikawa H. C5 palsy after decompression surgery for cervical myelopathy: Review of the literature. *Spine*. 2003; 28(21):2447-51. [DOI:10.1097/01.BRS.0000090833.96168.3F] [PMID]
- [9] Katsumi K, Yamazaki A, Watanabe K, Ohashi M, Shoji H. Can prophylactic bilateral C4/C5 foraminotomy prevent postoperative C5 palsy after open-door laminoplasty? A prospective study. *Spine*. 2012; 37(9):748-54. [DOI:10.1097/BRS.0b013e3182326957] [PMID]
- [10] Komagata M, Nishiyama M, Endo K, Ikegami H, Tanaka S, Imakiire A. Prophylaxis of C5 palsy after cervical expansive laminoplasty by bilateral partial foraminotomy. *The Spine Journal*. 2004; 4(6):650-5. [DOI:10.1016/j.spinee.2004.03.022] [PMID]
- [11] Sodeyama T, Goto S, Mochizuki M, Takahashi J, Moriya H. Effect of decompression enlargement laminoplasty for posterior shifting of the spinal cord. *Spine*. 1999; 24(15):1527-31. [DOI:10.1097/00007632-199908010-00005] [PMID]
- [12] Hashimoto M, Mochizuki M, Aiba A, Okawa A, Hayashi K, Sakuma T, et al. C5 palsy following anterior decompression and spinal fusion for cervical degenerative diseases. *European Spine Journal*. 2010; 19(10):1702-10. [DOI:10.1007/s00586-010-1427-5] [PMID] [PMCID]
- [13] Imagama S, Matsuyama Y, Yukawa Y, Kawakami N, Kamiya M, Kanemura T, et al. C5 palsy after cervical laminoplasty: A multicentre study. *The Journal of Bone and Joint Surgery. British Volume*. 2010; 92(3):393-400. [DOI:10.1302/0301-620X.92B3.22786] [PMID]
- [14] Katsumi K, Yamazaki A, Watanabe K, Ohashi M, Shoji H. Analysis of C5 palsy after cervical open-door laminoplasty: Relationship between C5 palsy and foraminal stenosis. *Clinical Spine Surgery*. 2013; 26(4):177-82. [DOI:10.1097/BSD.0b013e31823db346] [PMID]
- [15] Sasai K, Saito T, Akagi S, Kato I, Ohnari H, Iida H. Preventing C5 palsy after laminoplasty. *Spine*. 2003; 28(17):1972-7. [DOI:10.1097/01.BRS.0000083237.94535.46] [PMID]